



Short communication

Real-time TCD-vEEG monitoring for neurovascular coupling in epilepsy

Yuan Yao¹, Qiang Lu¹, Li-Ri Jin, Xiang-Qin Zhou, Yan Huang, Wei-Hai Xu*

Department of Neurology, Peking Union Medical College Hospital, Chinese Academy of Medical Sciences and Peking Union Medical College, Shuaifuyuan 1, Dong Cheng District, Beijing 100730, China

ARTICLE INFO

Article history:

Received 18 January 2015

Received in revised form 1 March 2015

Accepted 6 March 2015

Keywords:

Transcranial Doppler
Electroencephalography
Cerebral blood flow velocity
Partial seizures
Neurovascular coupling

ABSTRACT

Purpose: Recently, a novel multi-model monitor has been available, which integrates real-time signals of transcranial Doppler (TCD) and video-EEG (vEEG) into one workstation. We sought to test the feasibility of this device in detecting neurovascular coupling in patients with epilepsy.

Method: Cerebral blood flow velocity (CBFV) of bilateral middle cerebral arteries and vEEG during seizure episodes were recorded simultaneously in 12 patients (age 17–58 years) with partial epilepsies. The correlations between vEEG and CBFV findings were analyzed.

Results: Eleven seizure episodes were detected in 5 patients. Of them, bilateral CBFV increase with interhemispheric asymmetry was observed in 4 seizure episodes of 3 patients. EEG abnormalities preceded CBFV increase by 1–3 s at the onset of a seizure. In a patient with bilateral middle cerebral artery stenosis, no apparent CBFV changes were detected during 2 of 3 seizure episodes. Another patient with previous frontal hemorrhage displayed CBFV increase without interhemispheric asymmetry during 4 seizure episodes.

Conclusion: It is feasible to evaluate neurovascular coupling with good temporal correlation in patients with frequent seizure episodes by real-time TCD-vEEG monitoring.

© 2015 British Epilepsy Association. Published by Elsevier Ltd. All rights reserved.

1. Introduction

It is known that epileptic discharges can evoke an increase of cerebral blood flow to meet the high metabolic demands due to intense neuronal activities. Such neurovascular coupling can be detected by the combination of electroencephalography (EEG) and transcranial Doppler (TCD). In previous studies, the signals of TCD and EEG were recorded by separate devices during seizure episodes and correlated off-line [1,2]. Given the inconvenience of detection, only patients with very high frequency of seizure episodes (up to 60 times per day) or inducible seizures (such as absence seizures) were studied. Recently, a novel multi-model monitor has been available, which integrates real-time signals of TCD and video-EEG (vEEG) into one workstation (NSD-8100, Delica China). In current study, we sought to test the feasibility of this device in evaluating epilepsy patients in routine clinical setting.

2. Methods

2.1. Patients

Consecutive 12 patients with drug-resistant partial epilepsies (age 17–58 years) were recruited from a presurgical evaluation program. Drug-resistant epilepsy was defined as a failure of adequate trials of 2 (or more) tolerated, appropriately chosen, and appropriately used antiepileptic drug regimens (whether administered as monotherapy or in combination) to achieve freedom from seizures [3]. Thorough inquiries of clinical details and history, complete neurological examination, long term vEEG monitoring and brain MRI were performed in all patients, in order to determine the diagnosis based on 1989 ILAE report. After presurgical antiepileptic drugs withdrawal, a seizure episode occurring at least once per day was required. Patients with poor temporal windows were excluded. All patients signed informed consent. The study was approved by the ethics committee of Peking Union Medical College Hospital.

2.2. TCD-vEEG monitoring

The multi-model monitor (Fig. 1A) is comprised of display system, EEG, video camera, and TCD. Patients were in supine

* Corresponding author. Tel.: +86 10 69156372; fax: +86 10 69156372.

E-mail addresses: yypumc@126.com (Y. Yao), luqiang@pumch.cn (Q. Lu), carlyangjlr@126.com (L.-R. Jin), zhouxiangyioo@126.com (X.-Q. Zhou), huangyan90@sina.cn (Y. Huang), xuwh@pumch.cn (W.-H. Xu).

¹ These authors contributed equally to the manuscript.

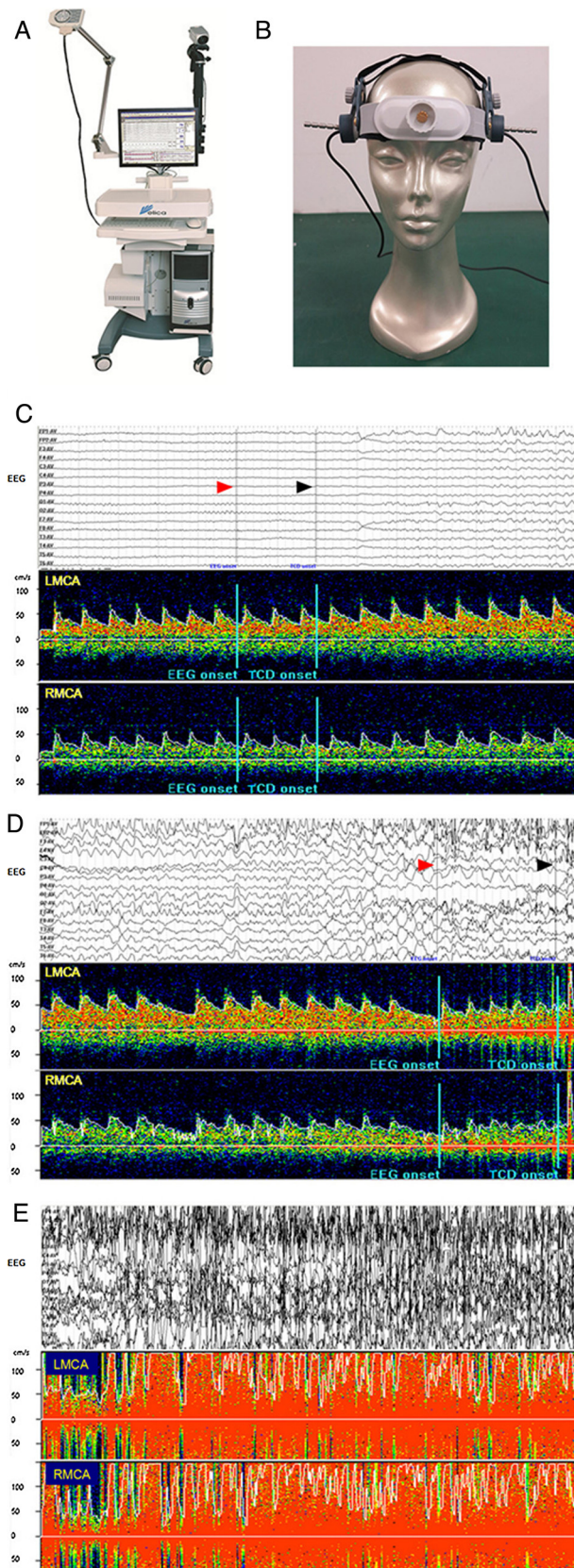


Fig. 1. Illustrations of EEG and CBFV at complex partial seizure onset, secondary generalized tonic-clonic seizure onset and during secondary generalized tonic-clonic seizure in case 2. The components of the multi-model TCD-vEEG monitor are shown in A and B. In the EEG interfaces, red arrowheads represent the EEG seizure onsets while black arrowheads indicate the TCD seizure onsets (C and D). Corresponding onsets are also labeled as 2 successive blue lines in the TCD interfaces (C and D). During an episode of complex partial seizure, CBFV increased

position during monitoring. EEG was obtained by standard 16-channel electroencephalograph with silver chloride scalp electrodes placed according to the 10–20 system. Simultaneous TCD was performed using 2 MHz pulsed-wave Doppler probes fixed to each temporal window by a helmet (Fig. 1B). The depth of acquiring optimal middle cerebral artery signals was 50–60 mm from both sides. A computer screen displayed video image, EEG and bilateral TCD signals including automatically calculated CBFV and envelope curve (Fig. e-1). All signals were recorded simultaneously during monitoring.

It was reported that when repetitive stimulation of the motor cortex produced muscle jerks similar to those occurring during simple partial seizure, CBFV increased by less than 10% [4]. Therefore the baseline CBFV was defined when the mean velocities had less than 10% variation for one minute before seizure onset. The presence of abnormal CBFV changes was defined if there was more than 10% increase or decrease compared to baseline CBFV. The recovery of CBFV was defined when abnormal CBFV returned to baseline and kept stable for one minute. Maximum CBFV was defined as the maximum mean velocity during a seizure episode.

Video recordings and EEG were reviewed by an epilepsy specialist (Dr. Lu) to determine the seizure onset and ending. Abnormal EEG onset was defined as the first EEG change within the time of first subjective or objective clinical change [5], and EEG ending was defined as when rhythmic or epileptiform discharges were replaced by diffuse attenuation or slowing [6]. A monitoring ended if (1) the subject recovered to normal conditions from a seizure episode, or (2) the subject declined further monitoring.

3. Results

Eleven seizure episodes were detected in 5 of 12 patients. All of the 5 patients had stable and sufficient CBFV signals during monitoring (mean monitoring time, 103.8 ± 93.0 min). Table 1 and Table e-1 summarize the clinical and monitoring data, respectively.

In case 1–3, four seizure episodes were detected, including one simple partial seizure, two complex partial seizures and one secondary generalized tonic-clonic seizure. Bilateral CBFV increases were detected in all these episodes. In addition, CBFV increases were always greater on the onset side than the contralateral side (19–184% higher) except for secondary generalized tonic-clonic seizure. The changes of CBFV started 1–3 s after EEG onset in case 1 and 2 (Fig. 1C–E, case illustration e-1). Visible EEG abnormalities during seizures were not detected in case 3 with probable occult peri-insular epilepsy.

There were 2 patients with cerebrovascular diseases as the probable cause of epilepsies (case 4 with old infarction and case 5 with left frontal lobe hemorrhage). During 2 out of 3 simple partial seizures in case 4, no apparent CBFV changes were detected (Fig. e-2, case illustration e-2). In case 5, left EEG onset and ictal symptomatology were suggestive of left frontal onset (right leg extension and right arm raising), but CBFV increase was greater on the right side during 3 out of 4 episodes. Compared to case 1 and 2, the time lags between EEG abnormalities and CBFV onset were considerably larger (33–95 s).

The monitoring was stopped in 7 patients before an episode, as they claimed intolerant to longer TCD monitoring (mean time, 144.1 ± 114.4 min).

2 s after EEG onset and showed interhemispheric asymmetry (44.7% increase on the left side and 37.5% on the right side compared to baseline) (C). The CBFV temporarily dropped to baseline followed by secondary generalized tonic-clonic seizure (D and E). During the secondary generalized tonic-clonic seizure, CBFV increased bilaterally and maintained throughout the episode (E). EEG = electroencephalography, TCD = transcranial Doppler, CBFV = cerebral blood flow velocity.

Table 1
Clinical data in 5 epileptic patients with seizure episodes during monitoring.

Patient Number	Age/sex	Etiology	Seizure focus location	Seizure focus side	Seizure frequency per month	Anti-epileptic drug
1	50/f	Cryptogenic	Frontal	Right	30 simple partial seizures +30 secondary generalized tonic-clonic seizures	Clonazepam
2	21/m	Ganglioglioma, focal cortical dysplasia	Temporal	Left	1–2 complex partial seizures	Carbamazepine, topiramate
3	24/m	Cryptogenic	Probably peri-insular	Possibly right	30 simple partial seizures +1 secondary generalized tonic-clonic seizure	Lamotrigine
4	56/f	Brain Infarction	Frontal	Left	300 simple partial seizures	Oxcarbazepine, levetiracetam
5	42/m	Arteriovenous malformation, brain hemorrhage, post-surgery softening lesion	Frontal	Left	60–90 simple partial seizures	Levetiracetam, topiramate, valproate

4. Discussion

In this study, the CBFV changes during epileptic seizures were detected by real-time TCD-vEEG monitoring. In 3 out of 5 cases, there was a CBFV increase, preceded by EEG and with greater amplification on the onset side. The findings were consistent with previous studies [7,8]. Niehaus et al. observed that the onset of abnormal epileptic discharges in simple partial seizures was accompanied by a rapid increase of flow velocity in the ipsilateral middle cerebral artery, but only minor changes in the contralateral middle cerebral artery [7]. Similar phenomenon was reported in another 2 patients with temporal lobe epilepsy and complex partial seizures [8]. A possible explanation of interhemispheric asymmetry is that early capillary dilation elicited by neuronal activity is highly localized and then passes in a retrograde fashion to arterioles and arteries [9]. The time lag between EEG abnormalities and CBFV changes could be interpreted as time needed for neurovascular coupling [1]. Such CBFV changes may assist lateralization of seizure onset zone [8]. Interestingly, in case 3 who had probable right peri-insular epilepsy onset judged by clinical symptoms, while EEG failed to reveal seizure activity, the CBFV increase showed right-side predominance.

In 2 out of 5 cases, the findings of TCD-vEEG suggested probable deficits in neurovascular coupling. Both cases had cerebrovascular diseases. The absence of CBFV increase in case 4 could be explained by impaired vasomotricity of stenotic middle cerebral arteries [10]. In case 5, the absence of interhemispheric asymmetry could possibly be attributed to the destruction of local arterioles after hemorrhage.

Our study suffered from several limitations. Firstly, the sample of current study is fairly small and heterogeneous which prevents further analysis. Secondly, only patients with partial epilepsies and relatively frequent seizure episodes were recruited, which possibly induced selection bias. A wider spectrum of epilepsy syndromes should be investigated in the future. Finally, six patients were excluded from the study due to poor temporal windows. It could be assumed in elderly patients with poorer detection windows, this yield of TCD-vEEG is limited. Also, the discomfort of the long TCD monitoring required further technique improvement.

Nevertheless, our study suggests that TCD-vEEG is a promising technique. Compared to traditional ictal SPECT or functional MRI, TCD-vEEG is inexpensive, portable and has the advantage of providing the temporal pattern of neurovascular coupling, as well as allowing a longer monitoring period so that more patients are eligible. Further studies are required to investigate whether this

device is helpful for differentiating non-epileptic seizures and presurgical localization of onset zone.

In conclusion, it is feasible to detect neurovascular coupling in epileptic patients by TCD-vEEG, which makes it convenient to analyze the signals of CBFV and EEG with good temporal correlation.

Conflict of interest statement

Wei-Hai Xu received the multi-model monitor (NSD-8100) and funding from Delica China. The remaining authors have no conflicts of interest.

Acknowledgments

The authors thank Ying-Huan Hu² and Shu Wang² for providing technical assistance in TCD-vEEG monitoring.

Appendix A. Supplementary data

Supplementary data associated with this article can be found, in the online version, at <http://dx.doi.org/10.1016/j.seizure.2015.03.002>.

References

- [1] Bek S, Kaşıkçı T, Genç G, Demirkaya S, Gökçil Z, Odabaşı Z. Lateralization of cerebral blood flow in juvenile absence seizures. *J Neurol* 2010;257:1181–7.
- [2] Bode H. Intracranial blood flow velocities during seizures and generalized epileptic discharges. *Eur J Pediatr* 1992;151:706–9.
- [3] Kwan P, Schachter SC, Brodie MJ. Drug-resistant epilepsy. *N Engl J Med* 2011;365:919–26.
- [4] Niehaus L, Röricht S, Scholz U, Meyer BU. Hemodynamic response to repetitive magnetic stimulation of the motor and visual cortex. *Electroencephalogr Clin Neurophysiol Suppl* 1999;51:41–7.
- [5] Jenssen S, Gracely EJ, Sperling MR. How long do most seizures last? A systematic comparison of seizures recorded in the epilepsy monitoring unit. *Epilepsia* 2006;47:1499–503.
- [6] Jin L, Inoue Y. Spontaneous periictal leaving behavior: a potential lateralizing sign in mesial temporal lobe epilepsy. *Epilepsia* 2009;50:1560–5.
- [7] Niehaus L, Wiesmann UC, Meyer B. Changes in cerebral hemodynamics during simple partial motor seizures. *Eur Neurol* 2000;44:8–11.
- [8] Knake S, Haag A, Pilgramm G, Reis J, Klein KM, Hoeffken H, et al. Ictal functional TCD for the lateralization of the seizure onset zone – a report of two cases. *Epilepsia* 2004;62:89–93.
- [9] Ma H, Geneslaw A, Zhao M, Suh M, Perry C, Schwartz TH. The importance of latency in the focal of perfusion and oxygenation changes associated with triggered afterdischarges in human cortex. *J Cereb Blood Flow Metab* 2009;29:1003–14.
- [10] Krainik A, Villien M, Troprès I, Attyé A, Lamalle L, Bouvier J, et al. Functional imaging of cerebral perfusion. *Diagn Interv Imaging* 2013;94:1259–78.

² Department of Neurology, Peking Union Medical College Hospital, Chinese Academy of Medical Sciences and Peking Union Medical College, Beijing, China.